



# Physical examination in paediatrics

Nabil El-Lababidi

KPDPM VFN a 1. LF UK

# Childhood division

- Newborn age.
- Infancy.
- Toddlerhood.
- Preschool age.
- School age.
- Puberty and adolescence.

# Physical examination

- Observation of the child, concentrating on his spontaneous behaviour.
- Based on the age of the child, enough time should be allowed for him to get accustomed with his surroundings.
- Examination of a child should begin after acquiring his consent.
- In small children after establishing a social contact.
- Small children can be examined in the arms or on the lap of their parents.

# Physical examination

- A child should be informed about the nature of the ongoing examination.
- Rapid movements and loud noises should be avoided while examining small children.
- Examination as a form of a game is recommended.
- Unpleasant examinations and examinations of painful body parts should be left till the end.

# Physical examination

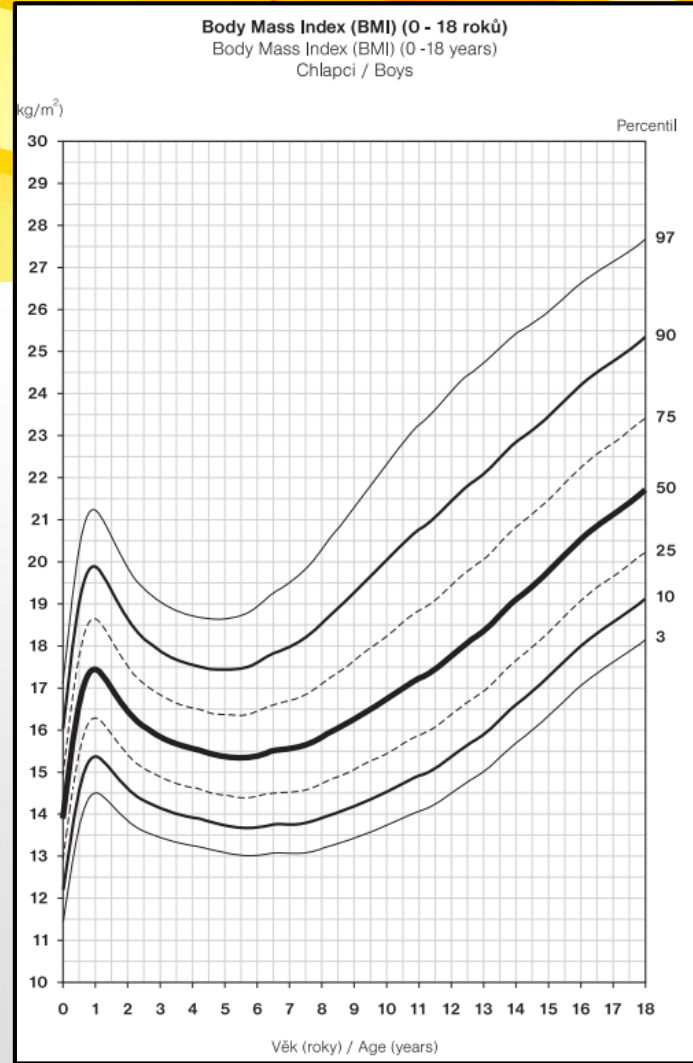
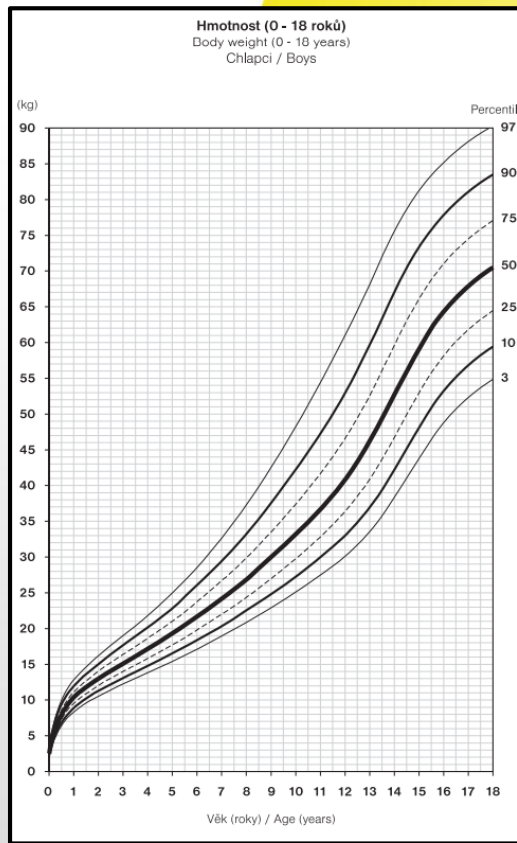
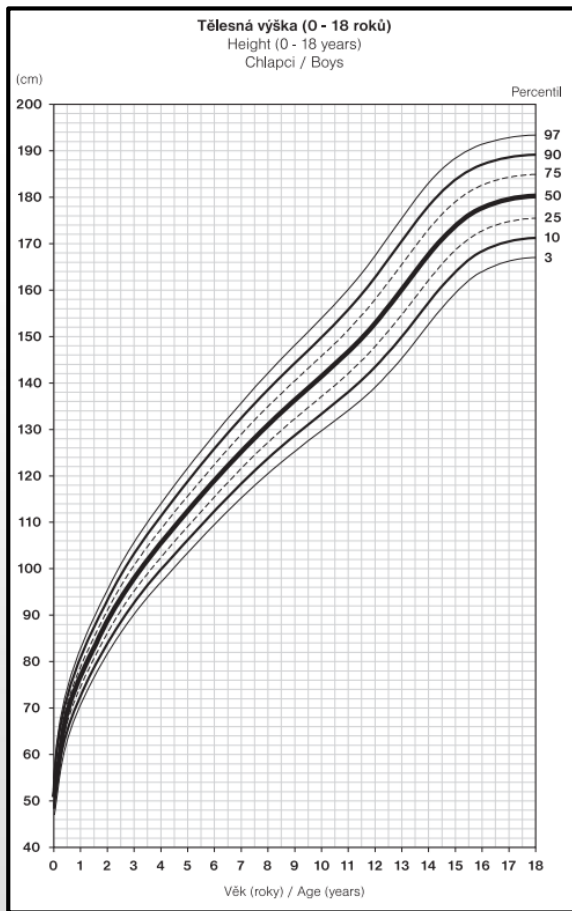
- An examination always begins with acquiring a detailed history.
- A child is always examined head to toes.
- The order in which the examinations take place depends on the acuity of the situation and the gravity of the health problems.

# Evaluation of general wellbeing

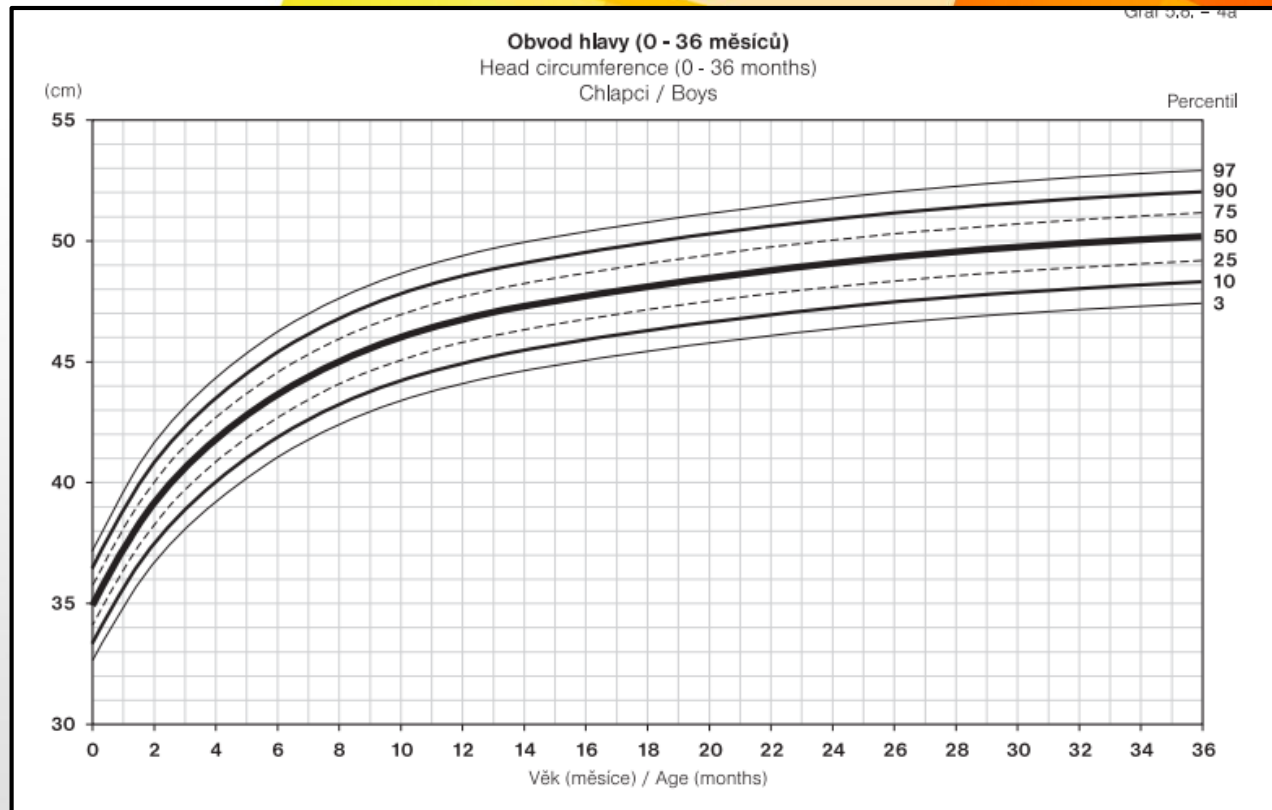
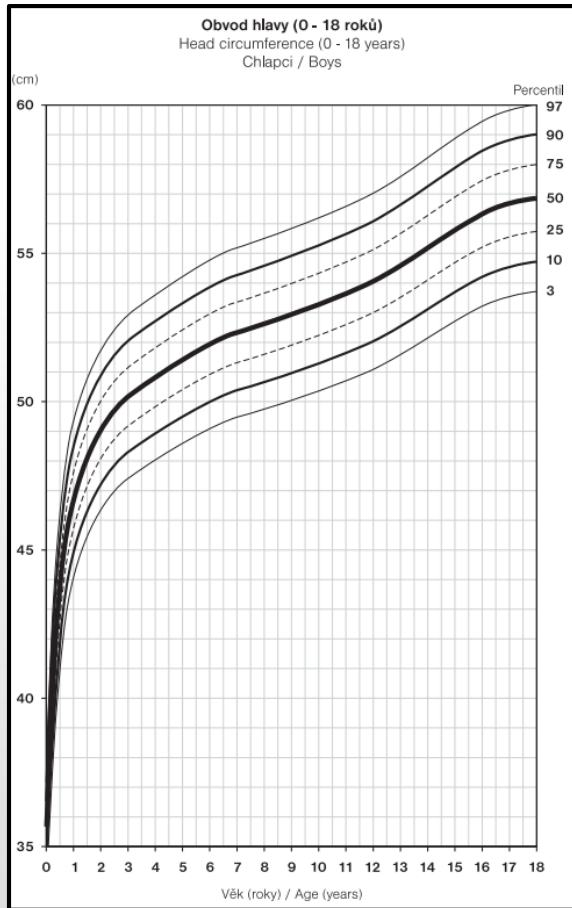
- Consciousness level.
- Spontaneous behaviour.
- Behaviour upon examination.
- Actively sought position.
- Evaluation of growth parameters:
  - Length/height.
  - Weight.
  - Weight-to-length percentile/BMI.
  - Head circumference.

# Percentile charts

[http://www.szu.cz/uploads/documents/obi/CAV/6.CAV\\_5\\_Rustove\\_grafy.pdf](http://www.szu.cz/uploads/documents/obi/CAV/6.CAV_5_Rustove_grafy.pdf)



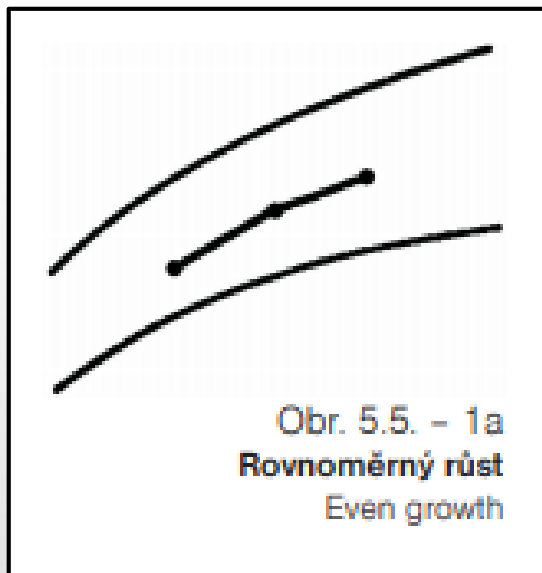


# Percentile charts



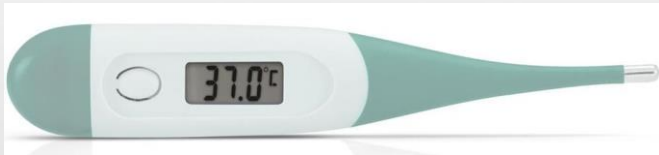

# Percentile charts

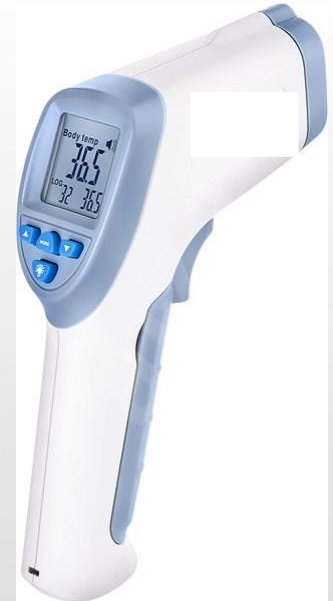
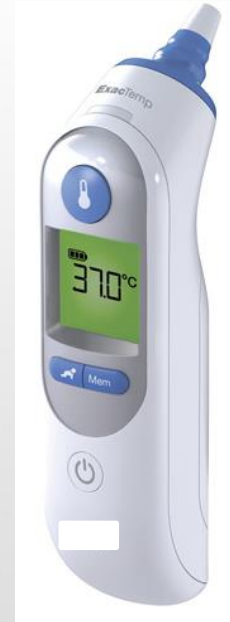
# Evaluation of general wellbeing

- Psychomotor development evaluation.
- Vital functions evaluation:
  - Body temperature.



<https://www.babysky.cz/digitalni-teploměr-green-bc-13gn/>



[https://www.ata.cz/uzivite-care-47-4724970.htm?kampaň=afw\\_2\\_domaci\\_elektro\\_plo\\_all\\_domaci\\_elektro\\_cis\\_28\\_avl\\_tplomery\\_c\\_3062874\\_C1250&cid=C&CQwww.0788888&sk\\_0788888&utm\\_source=sk&utm\\_medium=sk&utm\\_campaign=sk&utm\\_term=sk&utm\\_content=sk&utm\\_id=sk&utm\\_referrer=https://www.ata.cz/](https://www.ata.cz/uzivite-care-47-4724970.htm?kampaň=afw_2_domaci_elektro_plo_all_domaci_elektro_cis_28_avl_tplomery_c_3062874_C1250&cid=C&CQwww.0788888&sk_0788888&utm_source=sk&utm_medium=sk&utm_campaign=sk&utm_term=sk&utm_content=sk&utm_id=sk&utm_referrer=https://www.ata.cz/)

<http://www.apollostore.cz/cs/elektro-teplomery-usni-usni-teploměr-braun/p531527/c6898ie336is25.html>

# Heart rate

Age in years	BPM
< 1	110 – 160
1 – 2	100 – 150
2 – 5	95 – 140
5 – 12	80 – 120
> 12	60 - 100

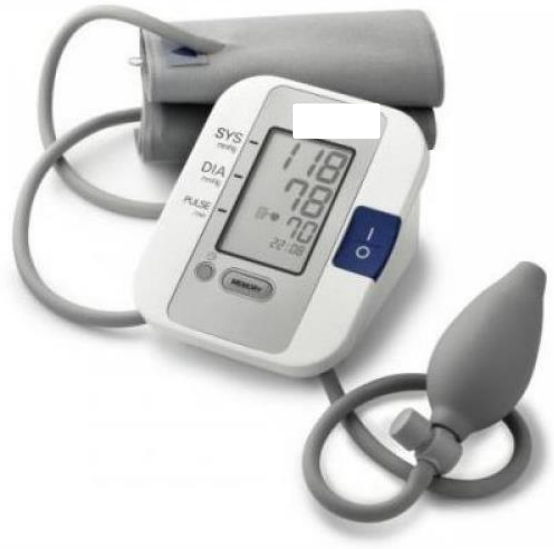# Breathing frequency

Age in years	Breaths per minute
Newborns	60
< 1	30 - 40
1 - 2	25 - 35
2 - 5	25 - 30
5 - 12	20 - 25
> 12	15 - 20

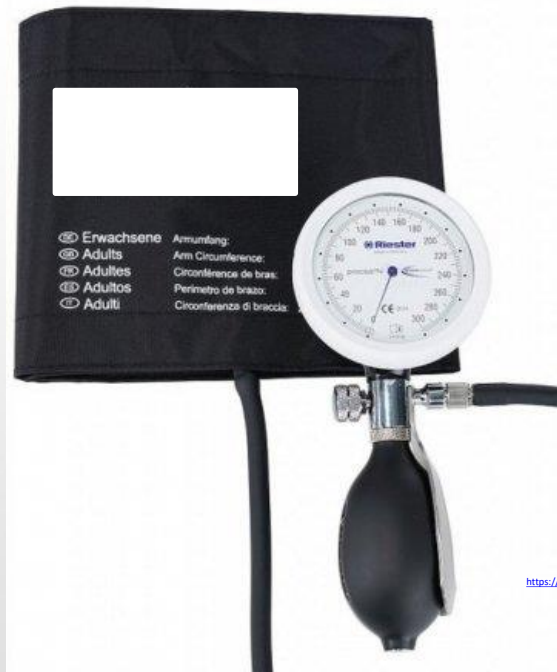# Systolic blood pressure

Age in years	Systolic blood pressure
Newborns	50 – 70
< 1	70 – 90
1 – 2	80 – 95
2 – 5	80 – 100
5 – 12	90 – 110
> 12	100 - 120

# Blood pressure measurement



<https://www.lekarna.cz/tonometr-digitalni-omron-m1-classic-poloautomaticky-pazni/2do-productReview-reviewForm>



<https://www.kalist.cz/produkt/3172-tonometr-riester-precia-schock-dietky-uredne-overeny>



[https://www.inset.cz/manzeta-pro-deti-mylon-2-hadice?ccid=Cj0KCQwwuD7BRDBARisAK\\_SyHW0y30J1P42LUJgvjil75ckIvtrSpI60x6m1woOx7n05vLr8LelaAvHEEAkw\\_wc](https://www.inset.cz/manzeta-pro-deti-mylon-2-hadice?ccid=Cj0KCQwwuD7BRDBARisAK_SyHW0y30J1P42LUJgvjil75ckIvtrSpI60x6m1woOx7n05vLr8LelaAvHEEAkw_wc)

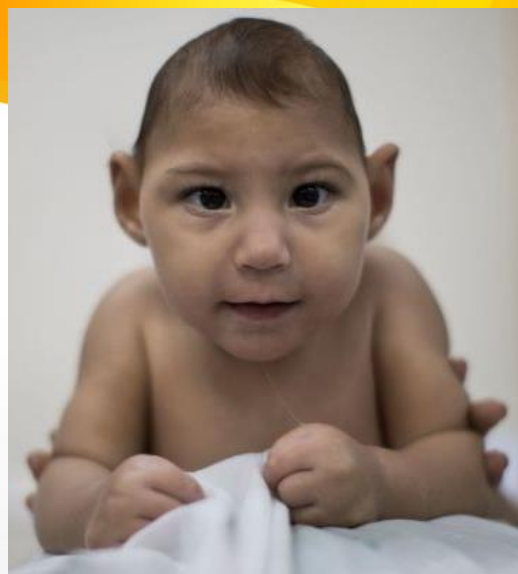# Percentile charts for blood pressure

Tabulka 7 Hodnoty krevního tlaku u dívek k výšce v percentilech

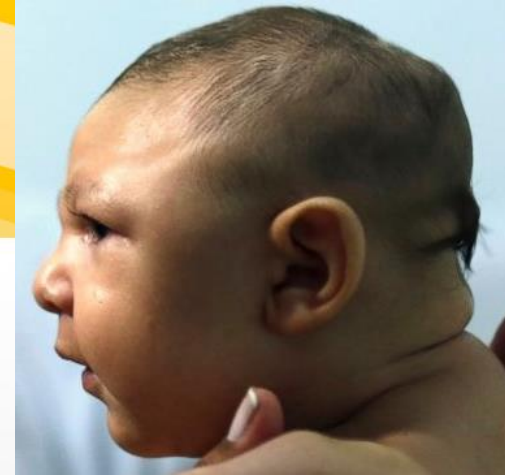Věk	TK percentily	Systolický TK, mm Hg, percentily výšky								Diastolický TK, mm Hg, percentily výšky							
		5.	10.	25.	50.	75.	90.	95.	5.	10.	25.	50.	75.	90.	95.		
1	50.	83	84	85	86	88	89	90	38	39	39	40	41	41	42		
	90.	97	97	98	100	101	102	103	52	53	53	54	55	55	56		
	95	100	101	102	104	105	106	107	56	57	57	58	59	59	60		
	99.	108	108	109	111	112	113	114	64	64	65	65	66	67	67		
2	50.	85	85	87	88	89	91	91	43	44	44	45	46	46	47		
	90.	98	99	100	101	103	104	105	57	58	58	59	60	61	61		
	95	102	103	104	105	107	108	109	61	62	62	63	64	65	65		
	99.	109	110	111	112	114	115	116	69	69	70	70	71	72	72		
3	50.	86	87	88	89	91	92	93	47	48	48	49	50	50	51		
	90.	100	100	102	103	104	106	106	61	62	62	63	64	64	65		
	95	104	104	105	107	108	109	110	65	66	66	67	68	68	69		
	99.	111	111	113	114	115	116	117	73	73	74	74	75	76	76		
4	50.	88	88	90	91	92	94	94	50	50	51	52	52	53	54		
	90.	101	102	103	104	106	107	108	64	64	65	66	67	67	68		
	95	105	106	107	108	110	111	112	68	68	69	70	71	71	72		
	99.	112	113	114	115	117	118	119	76	76	76	77	78	79	79		
5	50.	89	90	91	93	94	95	96	52	53	53	54	55	55	56		
	90.	103	103	105	106	107	109	109	66	67	67	68	69	69	70		
	95	107	107	108	110	111	112	113	70	71	71	72	73	73	74		
	99.	114	114	116	117	118	120	120	78	78	79	79	80	81	81		

# Head

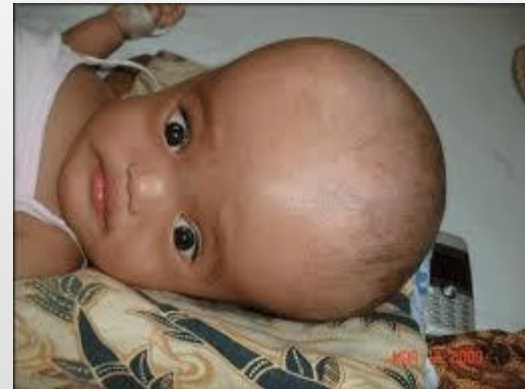- Shape:
  - Normocephalic.
  - Microcephalic.
  - Macrocephalic.



<https://www.latimes.com/science/sciencenow/la-sci-sn-zika-birth-defects-20170302-story.html>



<https://abcnews.go.com/health/zika-virus-confirmed-rare-microcephaly-birth-defect-cdc/story?id=38370364>

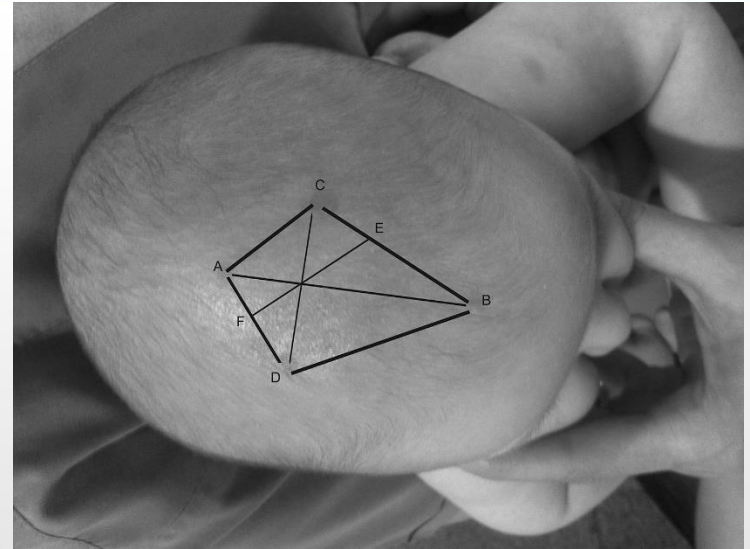

<https://www.omicsonline.org/singapore/hydrocephalus-peer-reviewed-pdf-ppt-articles/>



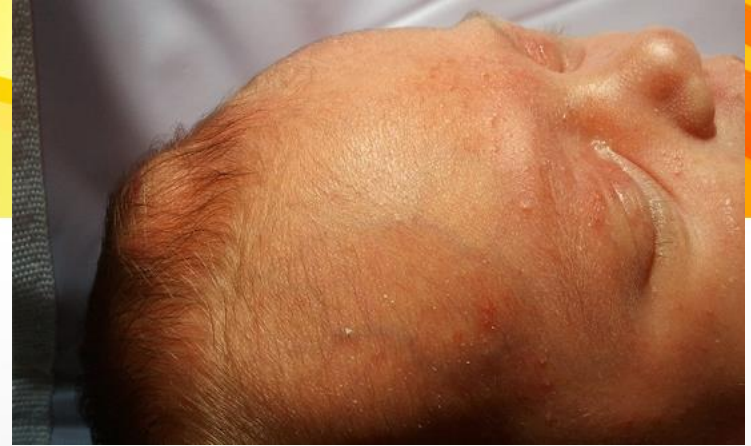# Head

- Large fontanel:
  - Size in centimetres.
  - Large.
  - Small.
  - Delayed closure.



# Head

- Level of the large fontanel:
  - Above the level of the skull.
  - Below the level of the skull.



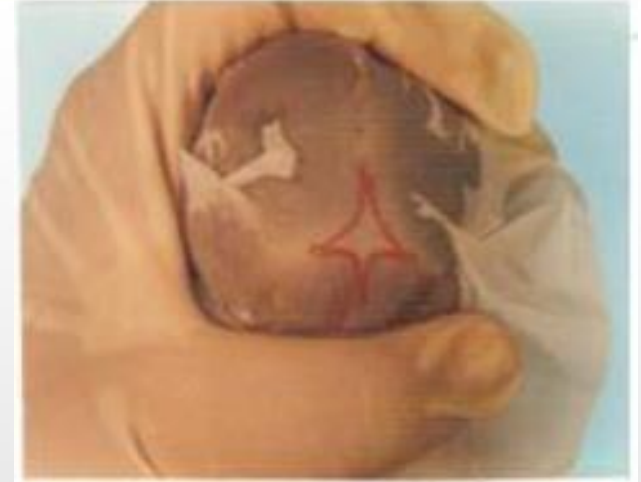<http://www.birthmarksupportgroup.org.uk/member-stories/elise%27s-story.aspx>



<https://community.whattoexpect.com/forums/october-2015-babies/topic/sunken-fontanelle-30.html>

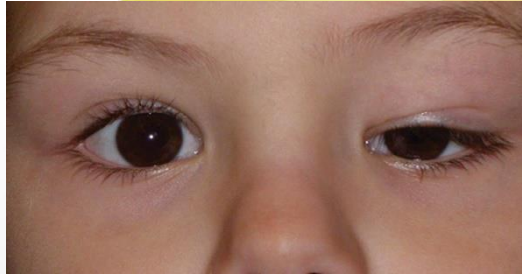# Head

- Small fontanel:
  - Physiologically up to three Months of age.
  - Down's syndrome.
  - Hypothyroidism.

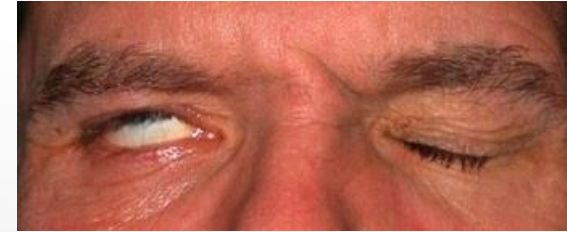

# Eyes

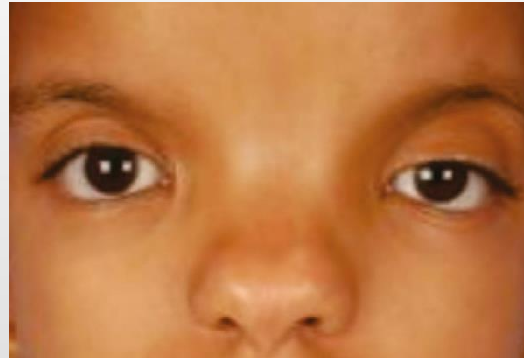- Eye fissures:
  - Symmetric.
  - Asymmetric.
  - Hypertelorism.
  - Epicanthus.



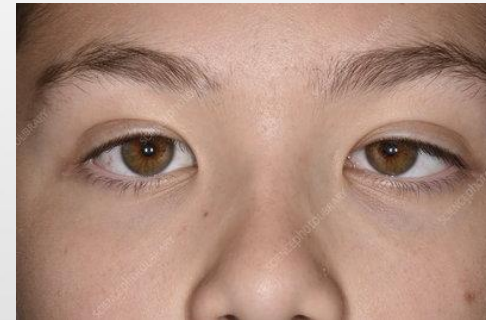<https://www.imo.es/en/childhood-eyelid-ptosis>



[https://www.physio-pedia.com/Dry\\_Eye](https://www.physio-pedia.com/Dry_Eye)



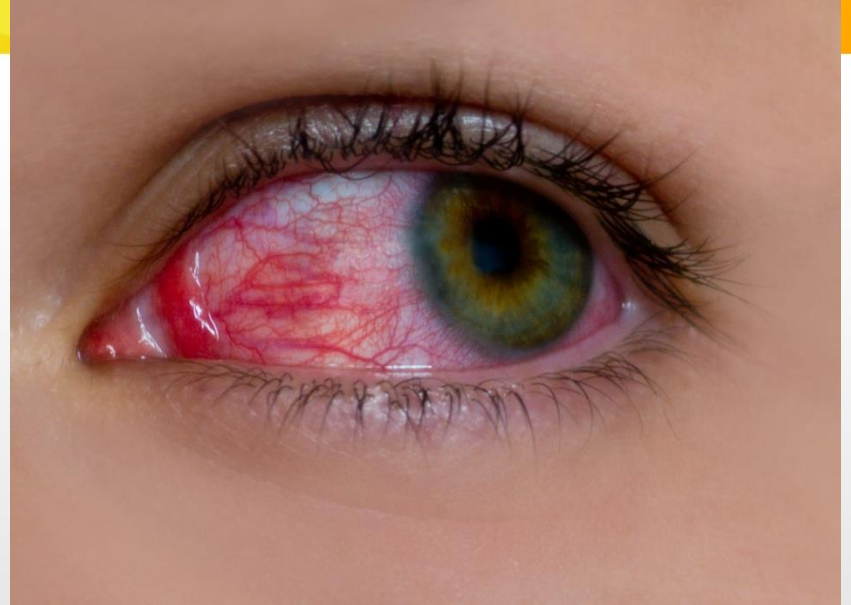<https://en.wikipedia.org/wiki/Hypertelorism>



<https://www.sciencephoto.com/keyword/epicanthal-fold>

# Eyes

- Cornea:
  - Pink.
  - Pale.
  - Red.

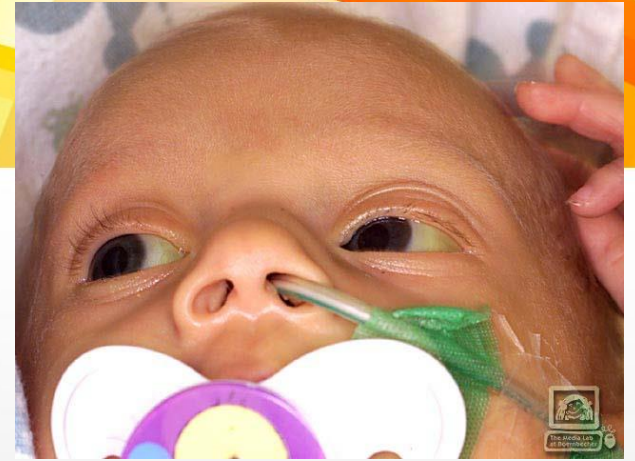

<https://www.netdoctor.co.uk/conditions/eyes/a10477/how-to-prevent-conjunctivitis/>

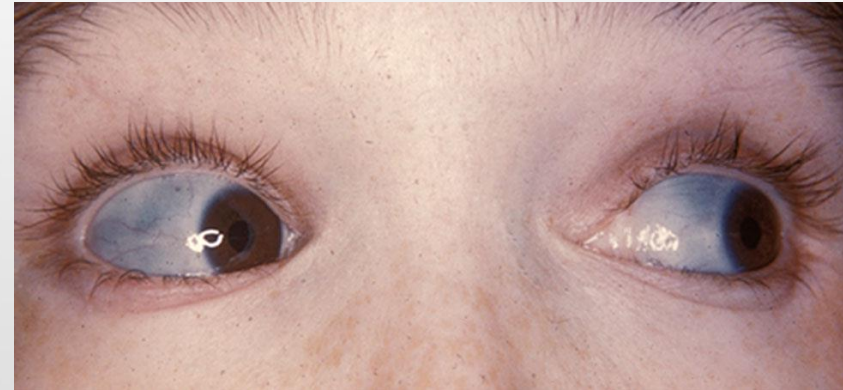

# Eyes

- Sclerae:
  - White.
  - Jaundiced.
  - Red.
  - Blue.



<https://pedsinreview.aappublications.org/content/22/7/219/tab-supplemental>



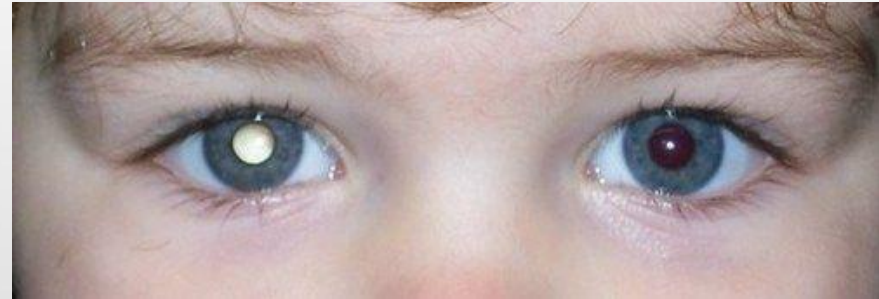[https://en.wikipedia.org/wiki/Osteogenesis\\_imperfecta](https://en.wikipedia.org/wiki/Osteogenesis_imperfecta)

# Eyes

- Pupils:
  - Isocoric, photoreactive.
  - Anisocoric, alternated photoreaction.
  - Amaurotic „cat’s“ eye.



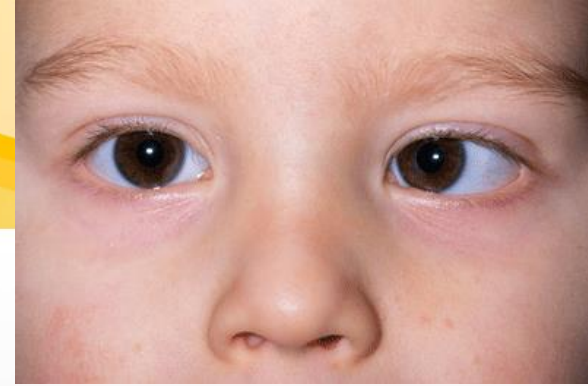<https://www.areasofmologica.com/ru/%D8%B4%D8%B1%D9%88%D8%B7-%D8%B7%D8%A8-%D8%A7%D9%84%D8%B9%D9%8A%D9%88%D9%86/%D8%AA%D9%81%D8%A7%D9%88%D8%AA-%D8%A7%D9%84%D8%AD%D8%AF%D9%82%D8%AA%D9%8A%D9%86/amp/>



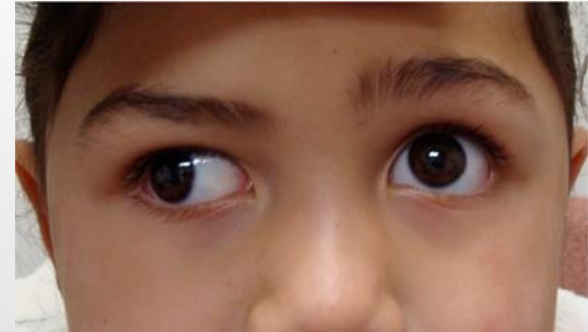<https://www.pinterest.com/pin/571394271443196178/>

# Eyes

- Eye bulbs:
  - In mid position, free motion.
  - Oculomotor nerves disorders.
  - Nystagmus.



<https://www.gponline.com/basics-strabismus/ophthalmology/article/1055827>

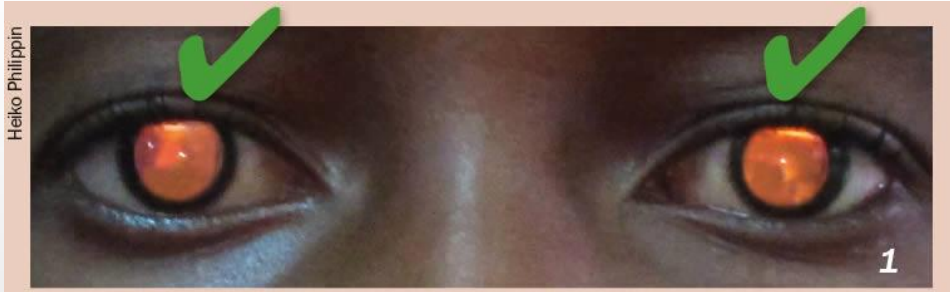

<https://eyedoctors.co.nz/services/childrens-eye-conditions/>

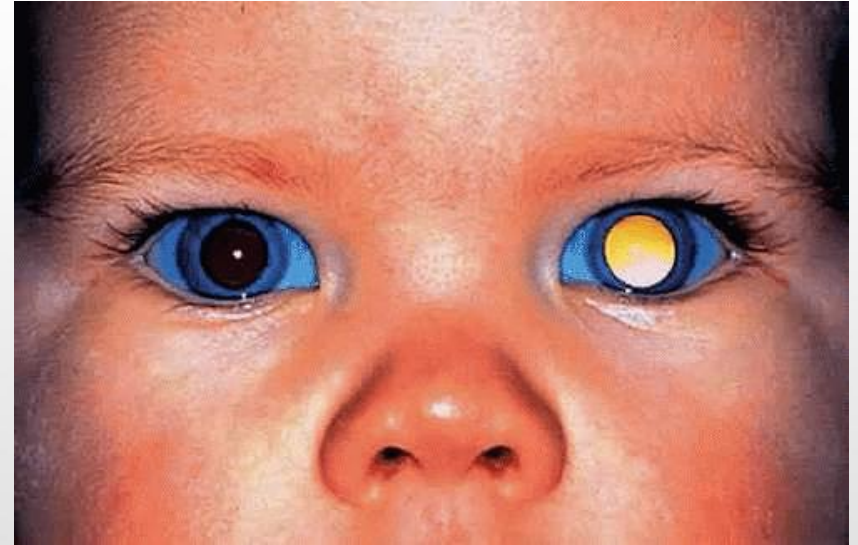

# Eyes

- Eye fundus - ophthalmoscopy.



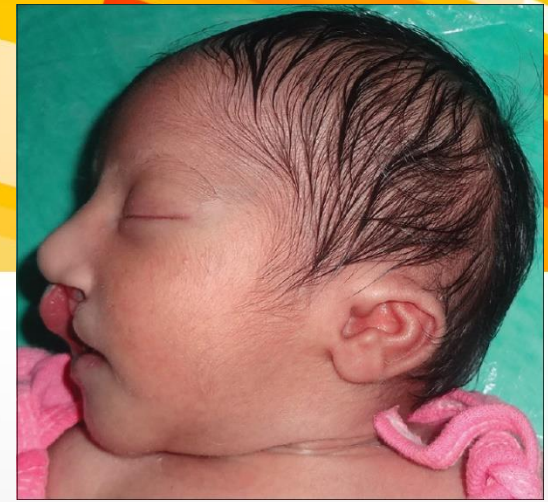<https://www.cehjournal.org/article/how-to-test-for-the-red-reflex-in-a-child/>



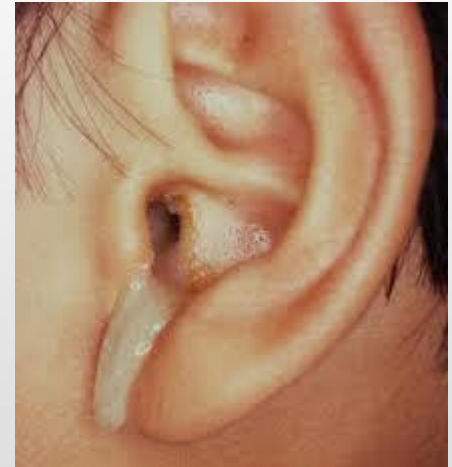<https://entokey.com/retinoblastoma-and-simulating-lesions/>

# Ears

- Ear lobes, external auditory channel:
  - Physiologic shape, no secretions.
  - Low set ears.
  - Ear discharge.



[https://www.icnonweb.com/viewimage.asp?img=IClinNeonatal\\_2015\\_4\\_3\\_193\\_154119\\_f4.jpg](https://www.icnonweb.com/viewimage.asp?img=IClinNeonatal_2015_4_3_193_154119_f4.jpg)



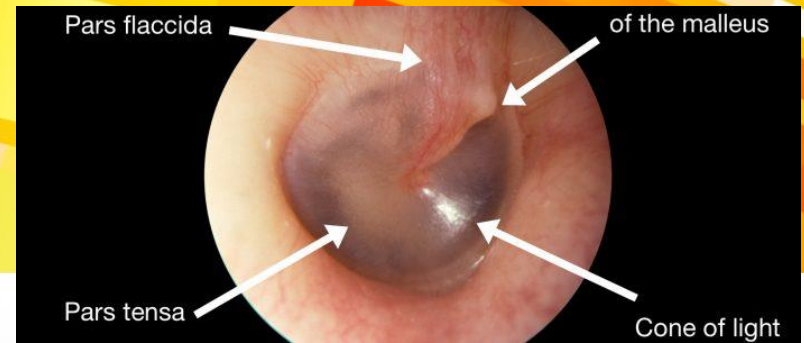<https://www.drannabelle.com/blog/ear-discharge-just-an-ear-infection-or-something-more-serious/>

# Ears

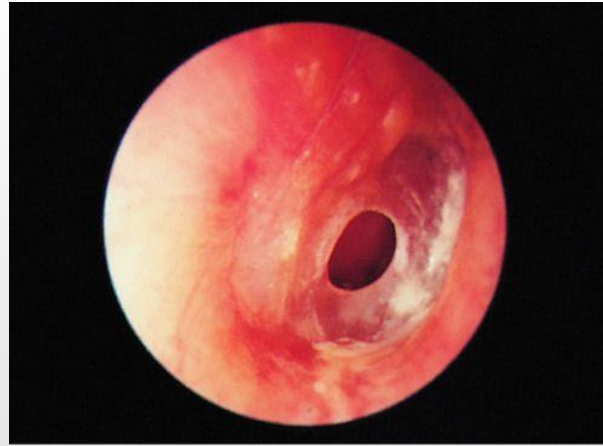
- Otoscopy.



[https://www.vseprovezdravi.cz/otoskop\\_eurolight](https://www.vseprovezdravi.cz/otoskop_eurolight)

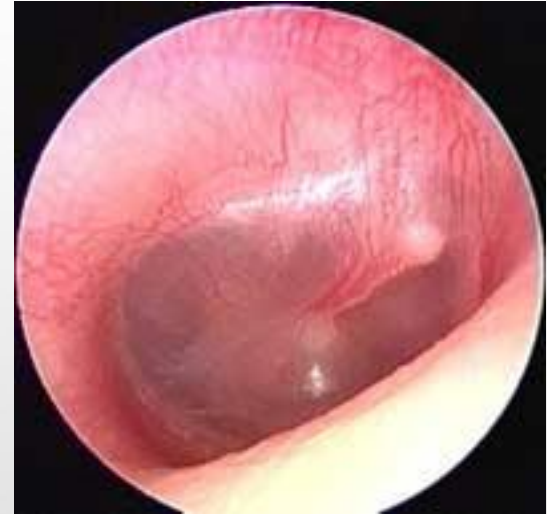

<https://geekymedics.com/hearing-ear-examination-osce-guide/>



(From Bingham, Hawkins, and Kocak, 1992.)

<https://www.pinterest.com/pin/171840542015236654/>



[https://www.rch.org.au/clinicalguide/guideline\\_index/Acute\\_otitis\\_media/](https://www.rch.org.au/clinicalguide/guideline_index/Acute_otitis_media/)

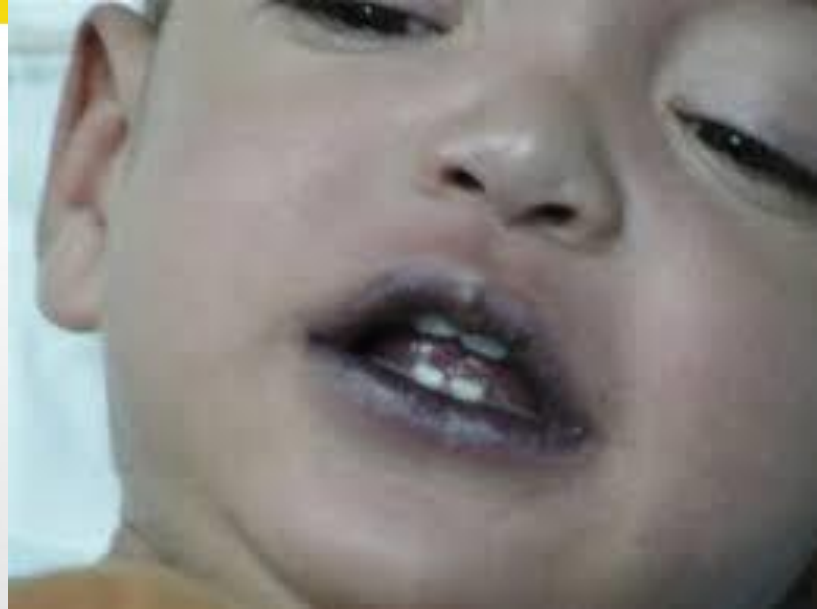# Nose

- Shape and size.
- Without secretions.
- With discharge:
  - Serous.
  - Purulent.
  - Haemorrhagic.



# Oral cavity

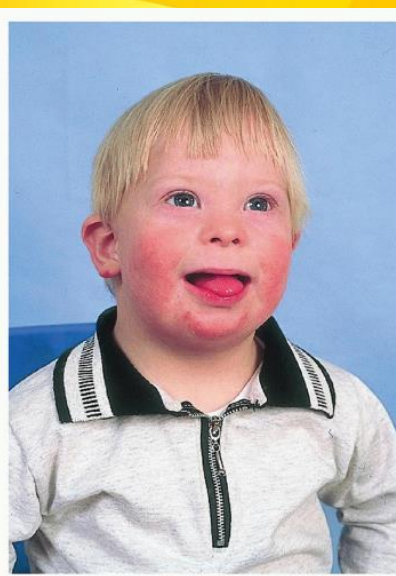- Lips:
  - Pink.
  - Cyanotic.
  - Pale.
  - Red.



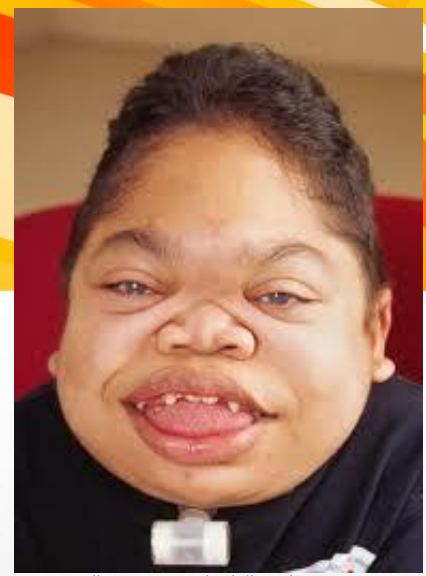

# Oral cavity

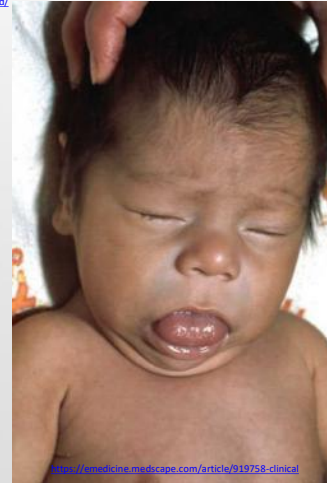- Tongue:
  - Sticks out in midline.
  - Moist/dry.
  - Macroglossia.



<https://entokey.com/the-syndromat-child/>



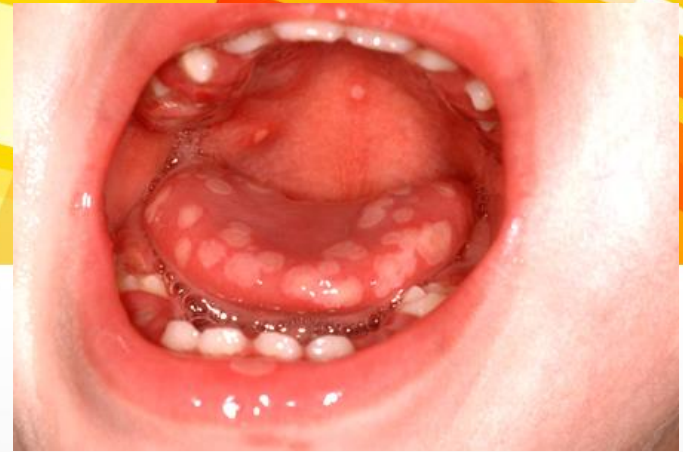<https://oird.biomedcentral.com/track/pdf/10.1186/1750-1172-5-5>



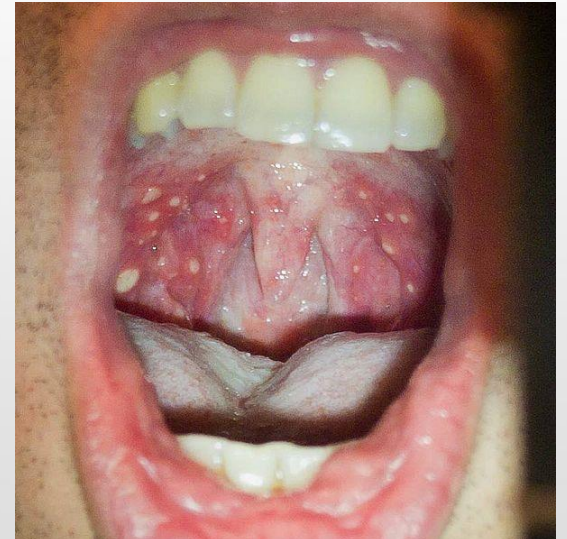<https://www.medscape.com/article/919758-clinical>

# Oral Cavity

- Oral mucosa and teeth gums:
  - Herpetic gingivostomatitis.
  - Hand-foot-mouth disease.



[https://www.rch.org.au/clinicalguide/guideline\\_index/HSV\\_Gingivostomatitis/](https://www.rch.org.au/clinicalguide/guideline_index/HSV_Gingivostomatitis/)



<http://outbreaknewstoday.com/vietnam-more-than-10000-hand-foot-and-mouth-disease-cases-reported-to-date-ho-chi-minh-city-reports-increase-in-recent-weeks-19172/>

# Oral cavity

- Dentition.



7 - 9 month



10 - 12 month



12 - 16 month



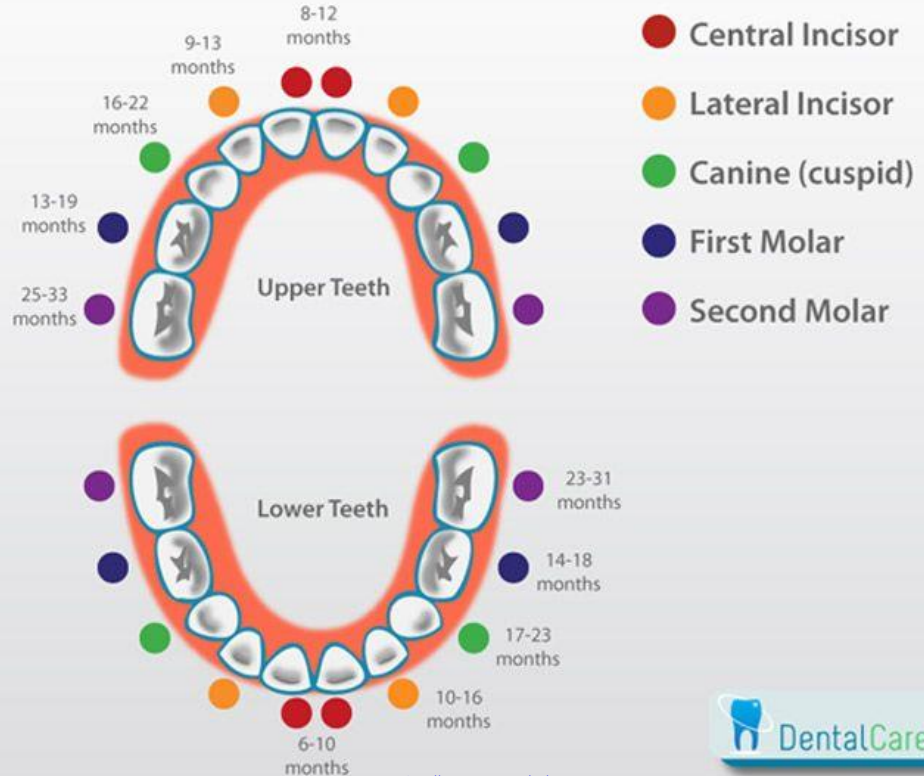
16 - 20 month



24 - 30 month



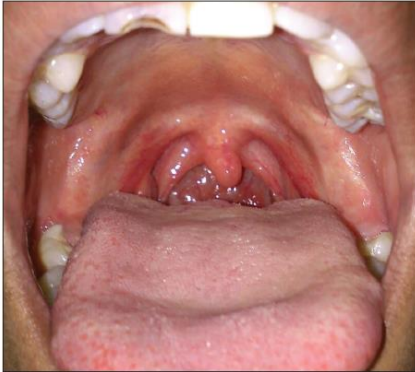## Baby Teeth Order



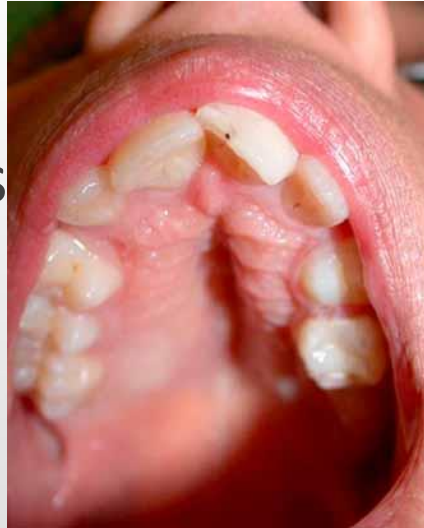

# Oral cavity

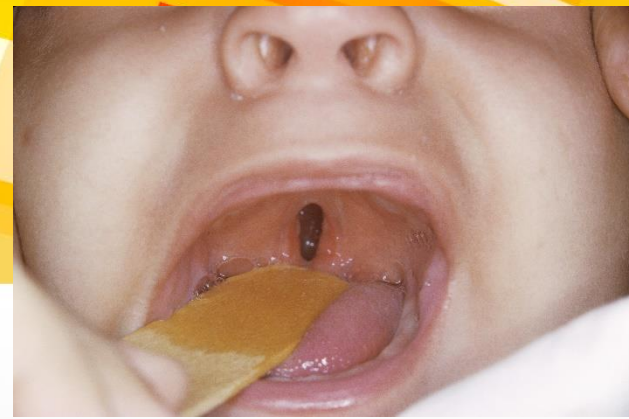- Palate and palatal arches:
  - Cleft disorders.
  - Gothic palate.
  - Asymmetric arches



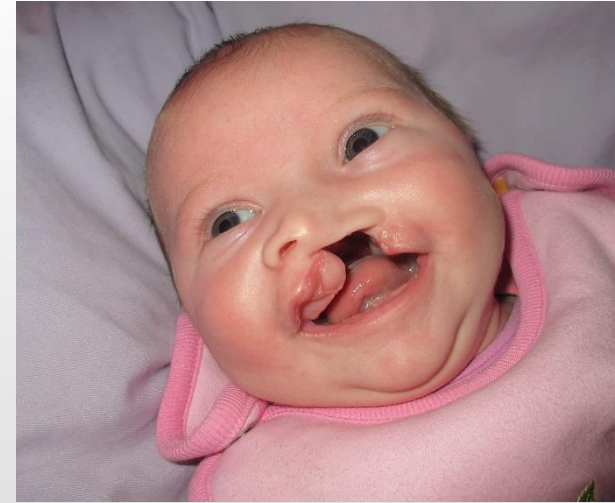<https://mjjournal.net/article/view/1120>



<https://elementsofmorphology.nih.gov/index.cfm?tid=70&id=128965515c4>



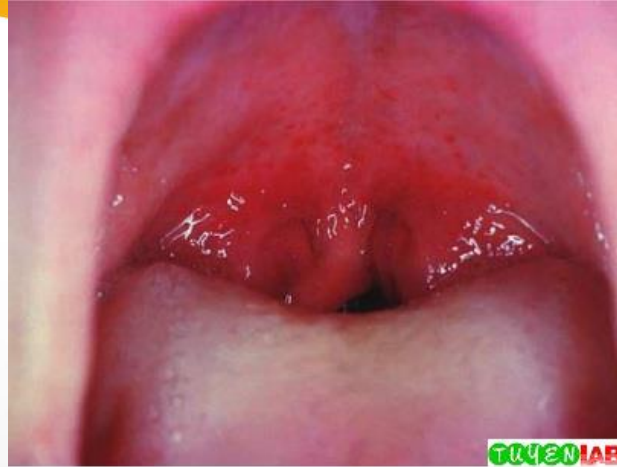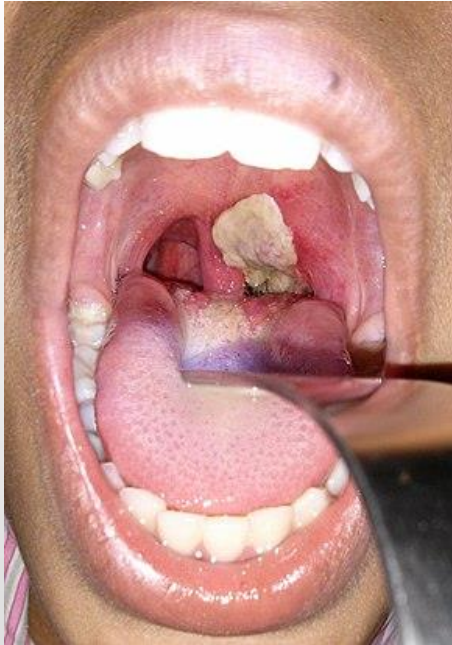<https://www.msmanuals.com/professional/pediatrics/congenital-craniofacial-and-musculoskeletal-abnormalities/cleft-lip-and-cleft-palate>



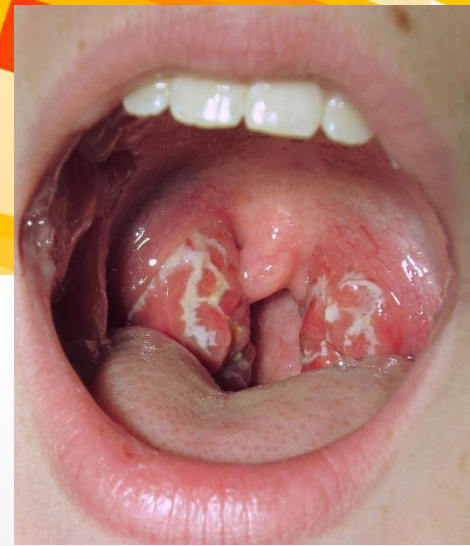<https://wmsmile.com/understanding-cleft-lips-and-palates-and-your-treatment-options/>

# Oral cavity

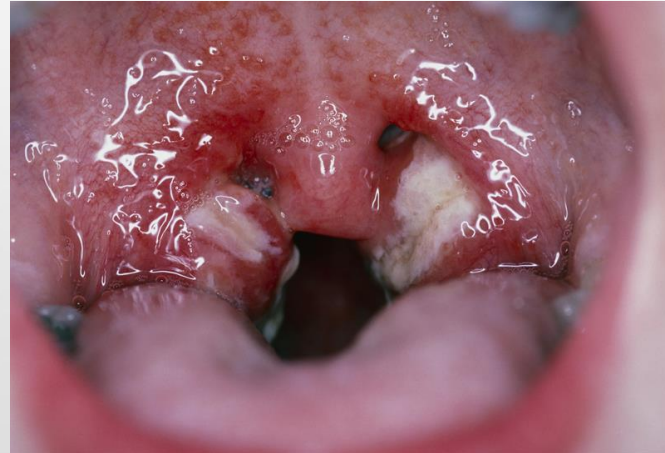- Tonsills.



<https://www.tuyenlab.net/2016/08/pediatric-atlas-of-upper-respiratory.html>



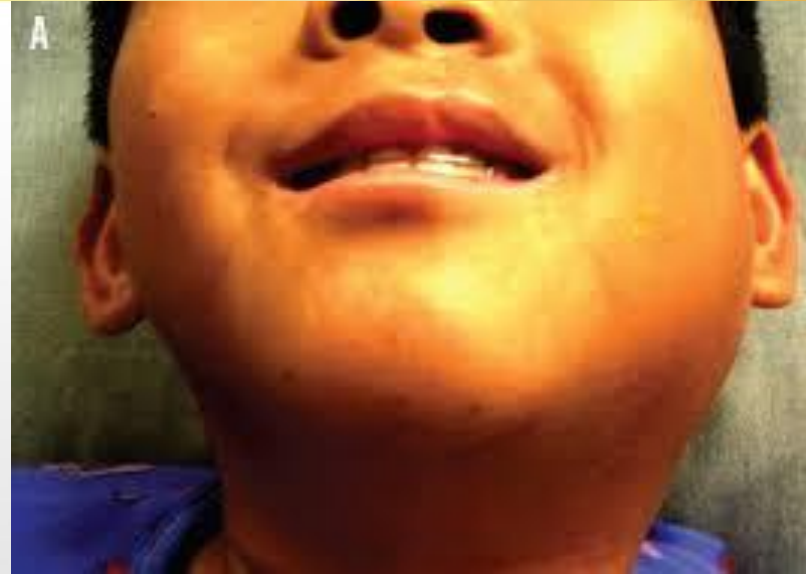<https://en.wikipedia.org/wiki/Tonsillitis>



<https://www.independentnurse.co.uk/clinical-article/diagnosis-and-management-of-glandular-fever-in-primary-care/223982>

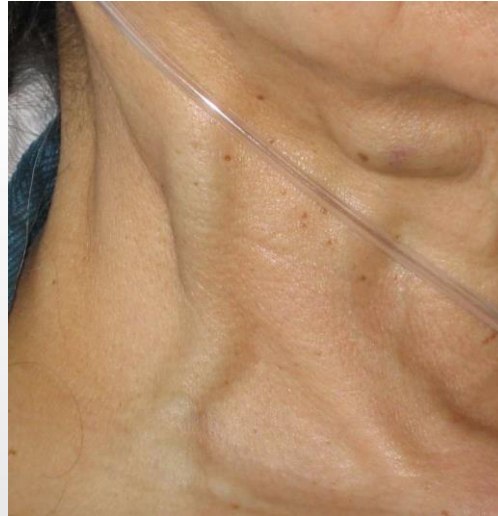# Oral cavity

- Salivary glands.

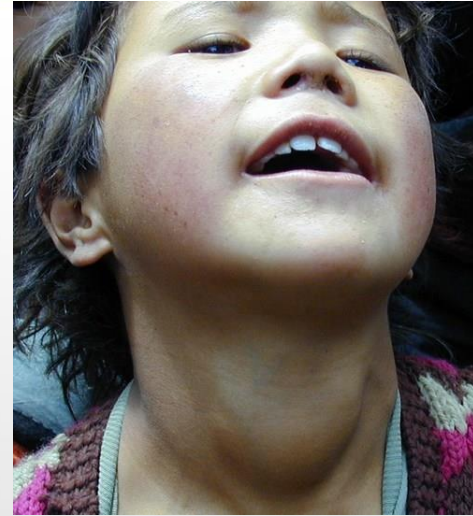

# Neck

- Neck shape.
- Its motility.
- Thyroid gland.
- Neck veins filling.



<https://www.medicalnewstoday.com/articles/320320>

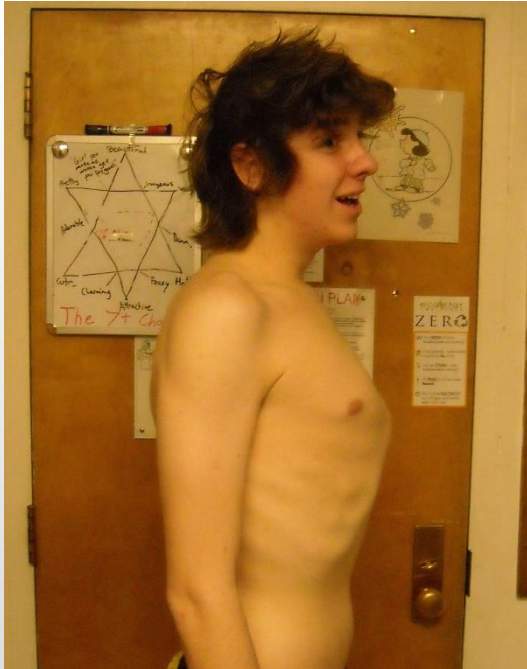

<https://www.ncbi.nlm.nih.gov/books/NBK285556/>

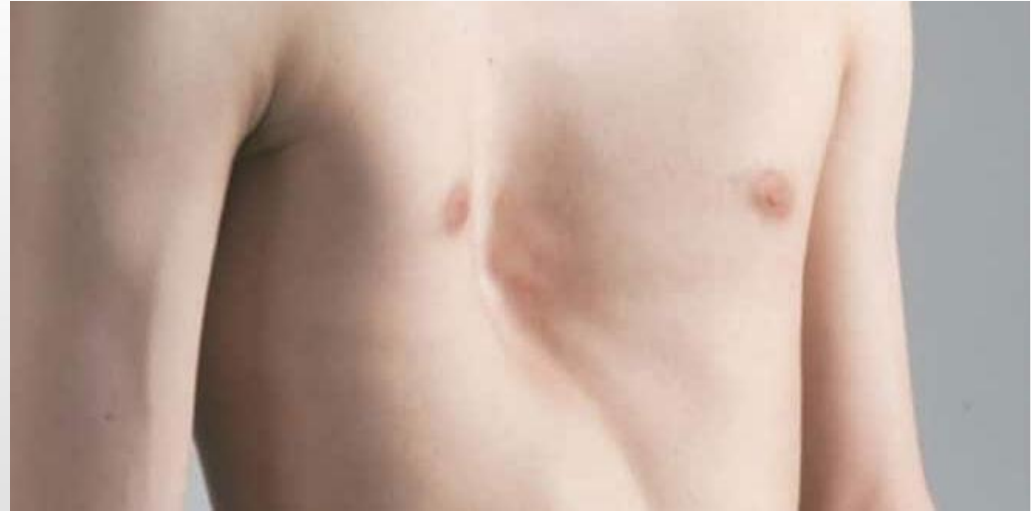

# Chest

- Chest size and shape.



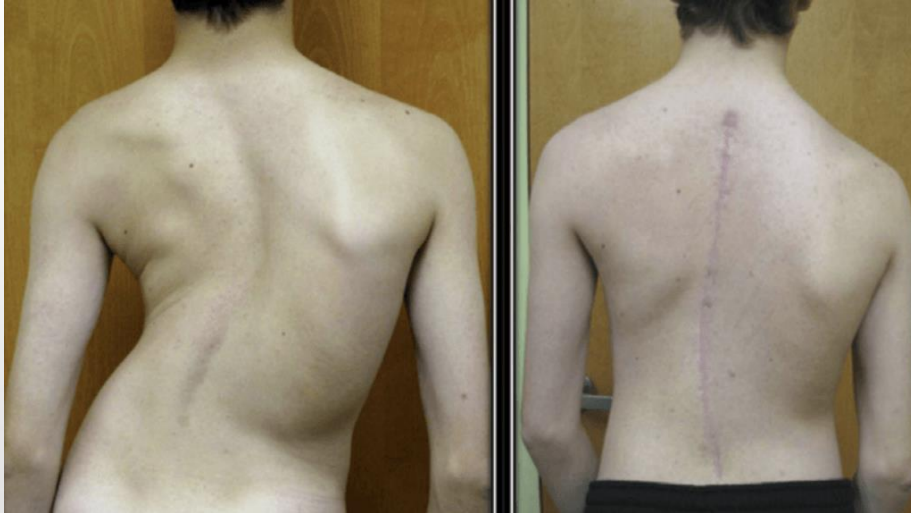[https://en.wikipedia.org/wiki/Pectus\\_carinatum](https://en.wikipedia.org/wiki/Pectus_carinatum)



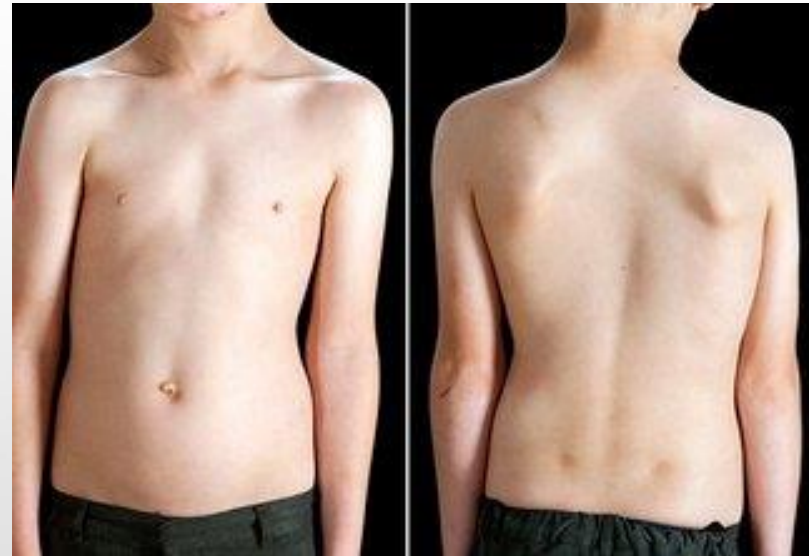<https://www.myhealthturkey.com/surgical-correction-of-pectus-excavatum-and-carinatum-deformities/>

# Chest

- Scoliosis.



<https://spinehealth.org/scoliosis-success-christians-story/>



<https://www.nhs.uk/conditions/scoliosis/>

# Chest

- Sternocostal joints.
- Lungs:
  - Auscultation:
    - Clear breathing.
    - Wheezing.
    - Crackles.
    - Tubal breathing.
    - Weakened breathing/silent lung.

# Chest

- Lungs:
  - Bronchophony.
  - Percussion:
    - Full.
    - Dull.
    - Hyperresonant.



# Chest

- Lungs:
  - Fremitus pectoralis:
    - Weakened.
    - Louder.

# Chest

- Lungs:
  - Objective symptoms of dyspnoea:
    - Nasal flaring.
    - Jugular retractions.
    - Retractions of intercostal/subcostal recessions.
    - Inspiratory position of the chest.
    - Orthopneic position.

# Chest

- Heart:
  - Local of heart apex beat.
  - Auscultation:
    - 2 heart sounds, no murmurs.
    - Heart beat irregularity on auscultation.
    - Murmurs:
      - Systolic.
      - Diastolic.
      - Continuous.

# Abdomen

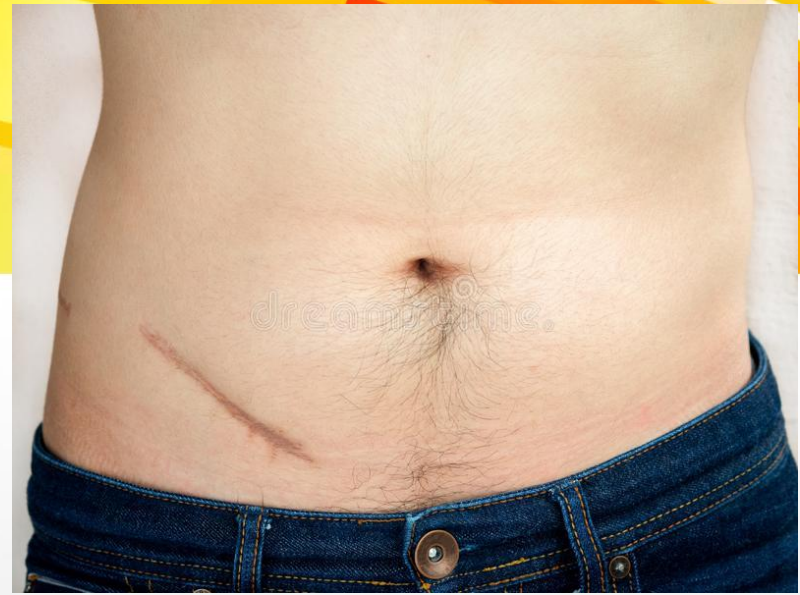- Level of the abdomen:
  - In the levels of the chest.
  - Below the level of the chest.
- Breathing wave.
- Scars.

# Abdomen

- Percussion:
  - Differentiated.
  - Dull.
  - Hyperresonant.

# Abdomen

- Palpation:
  - Superficial.
  - Deep.
  - Peritoneal irritation signs:
    - Blumberg's.
    - Plénies'.
    - Rowsing's.



<https://www.dreamstime.com/photos-images/scar-appendicitis.html>

# Abdomen

- Liver:
  - Liver size.
  - Palpation of the liver.
- Spleen:
  - Spleen size.
  - Palpation of the spleen.

# Abdomen

- Kidneys:
  - Israeli manoeuvre.
  - Tapottment.

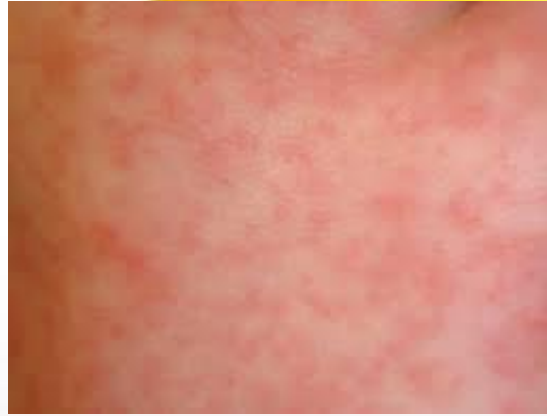

# Extremities

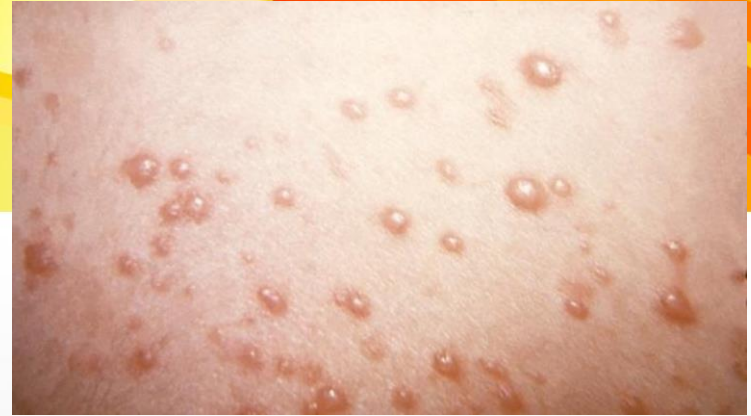- Configuration of extremities.
- Their symmetry.
- Joints:
  - Shape.
  - Size.
  - Symmetry.
  - Range of motion.

# Skin

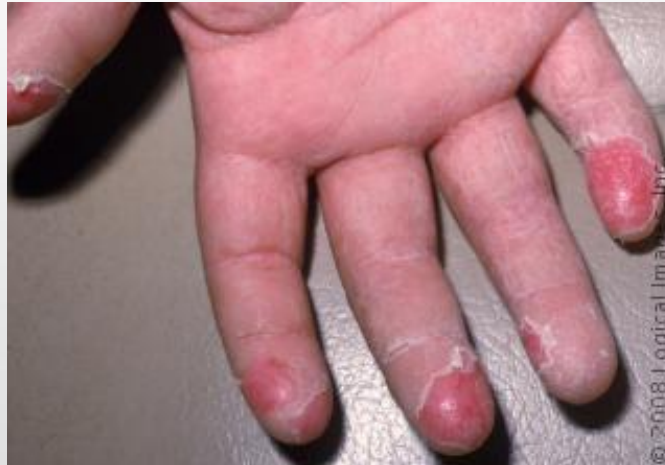- Colour.
- Scars.
- Rashes.



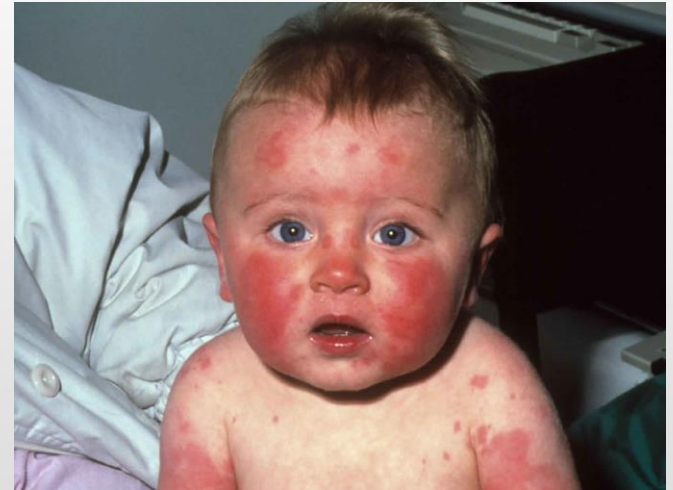<https://dermnetnz.org/topics/roseola/>



<https://www.kgun9.com/news/national/the-chickenpox-vaccine-reactivated-in-two-boys-doctors-think-its-the-first-time-its-ever-happened>



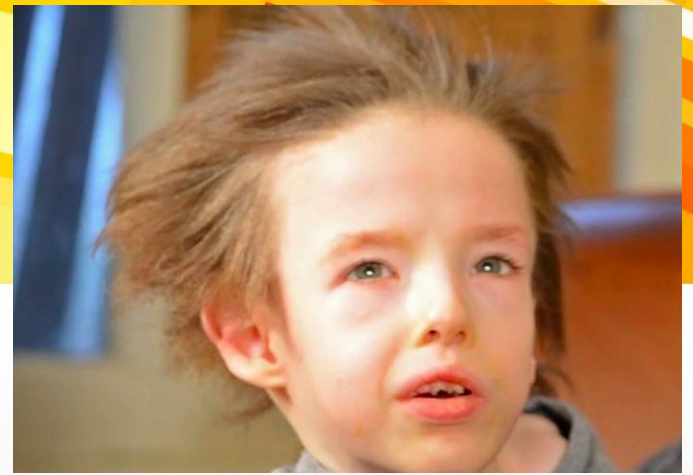<https://www.pinterest.com/pin/156077943309420807/>



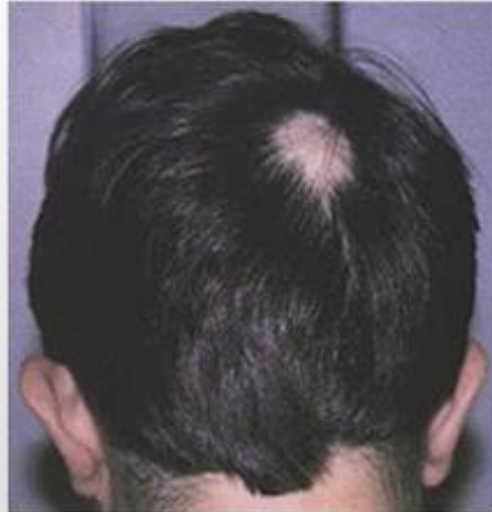<https://healthjade.net/erythema-infectiosum/>

# Hair

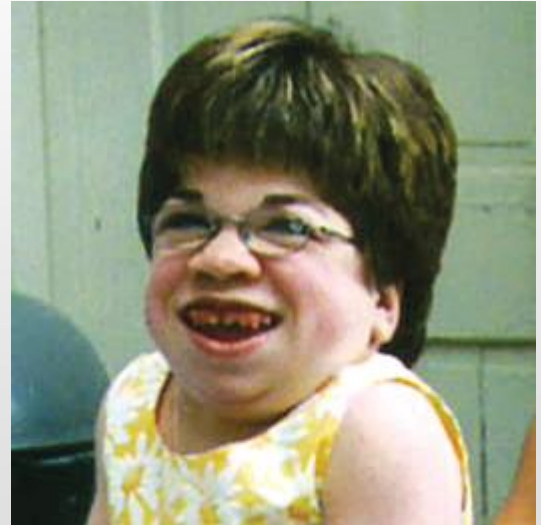- Distribution of head and body hair.
- Hair quality.



<https://globalgenes.org/2015/03/12/new-video-menkes-disease-finding-help-hope/>



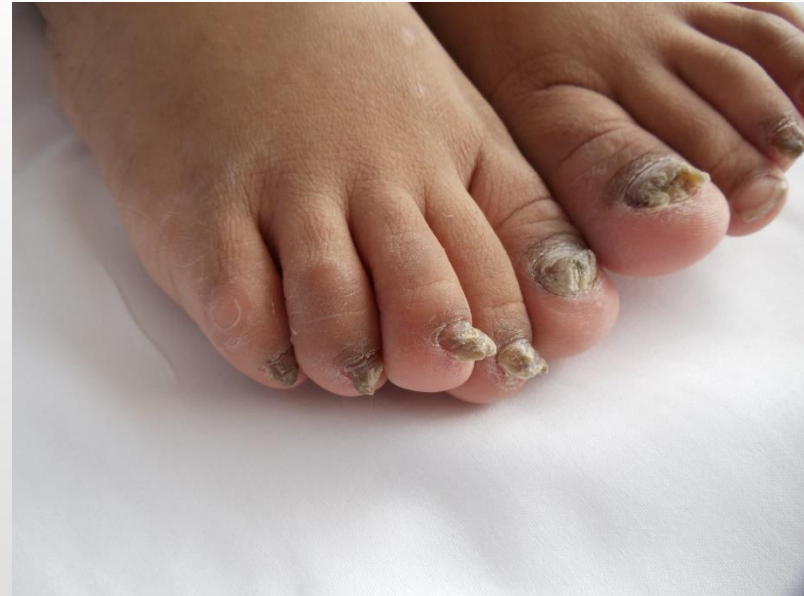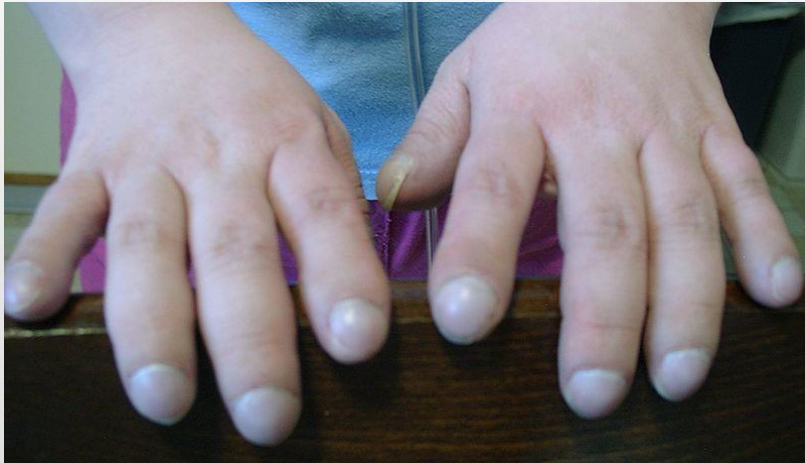<https://www.texaschildrens.org/blog/2013/01/what-alopecia-areata>



<https://www.mpsreference.com.au/management-and-treatment-of-mps/mps-vi-maroteaux-lamy-syndrome/>

# Nails

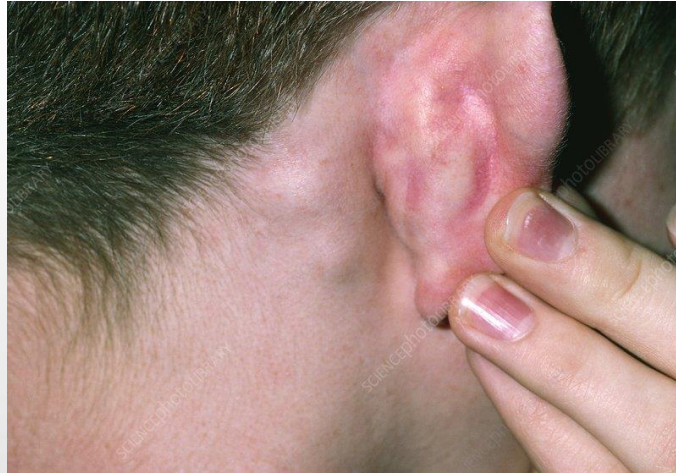- Nail shape.
- Their quality.
- Capillary refill time.



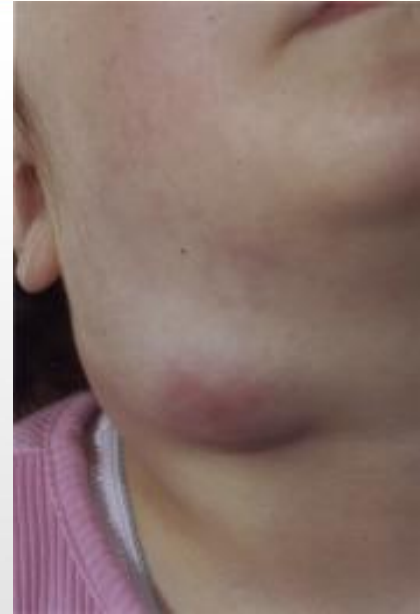

# Lymph nodes

- Location.
- Size.
- Consistency.
- Movement against surrounding tissues.
- Palpation sensitivity.



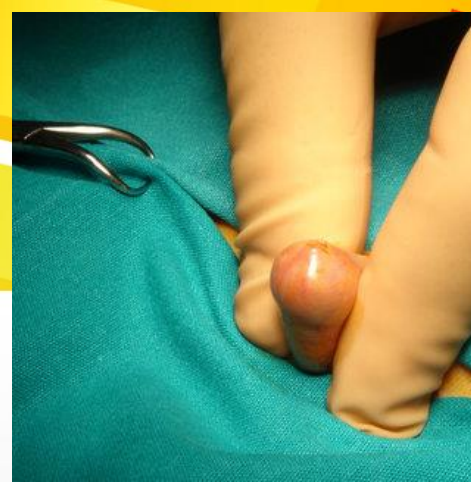<https://www.sciencephoto.com/media/259236/view/swollen-glands-lymphadenopathy-in-child-s-neck>



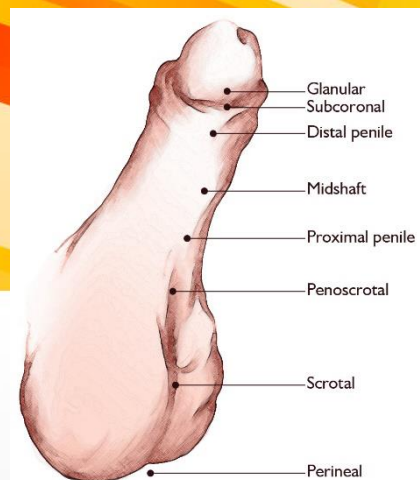
<https://www.sciencedirect.com/science/article/abs/pii/S1751722215002255>

# Genitals

- Male genitals:
  - Shape and size.
  - Location of outer urethra orifice.
  - Testicles.



[https://www.researchgate.net/publication/5533165\\_Sutureless\\_prepuceplasty\\_with\\_wound\\_healing\\_by\\_sec\\_ond\\_intention\\_An\\_alternative\\_surgical\\_approach\\_in\\_children%27s\\_phimosis\\_treatment/figures?lo=1&utm\\_source=google&utm\\_medium=organic](https://www.researchgate.net/publication/5533165_Sutureless_prepuceplasty_with_wound_healing_by_sec_ond_intention_An_alternative_surgical_approach_in_children%27s_phimosis_treatment/figures?lo=1&utm_source=google&utm_medium=organic)

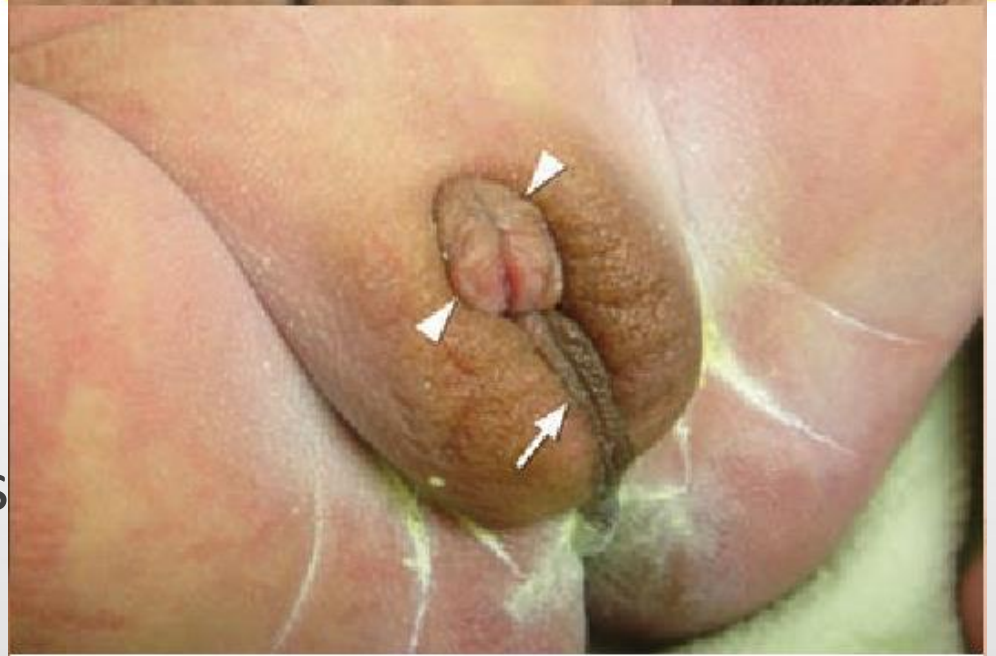

<https://www.choc.org/programs-services/urology/hypospadias-program/>



# Genitals

- Female genitals:
  - Shape and configuration.
  - Vaginal discharge.
- Indeterminate genitals



# Puberty evaluation

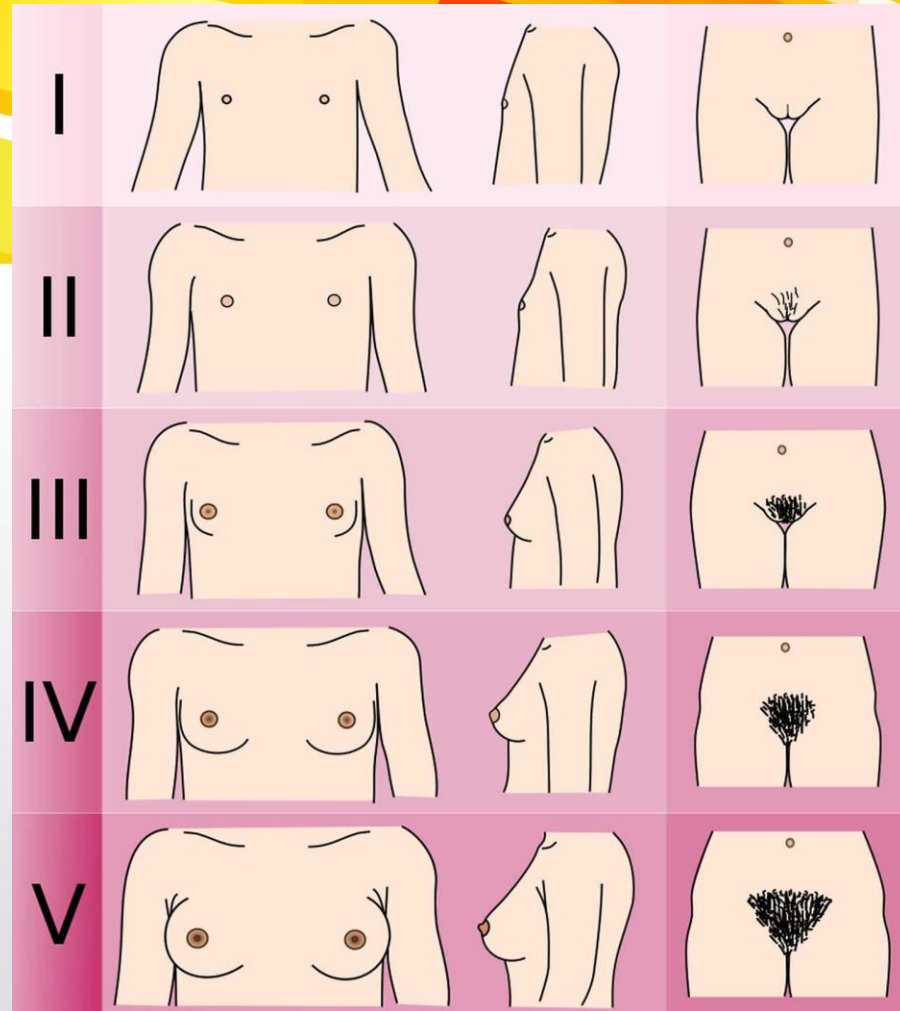
- Tanner classification.
- In boys.



I		3 ↕ <2,5
II		4 ↕ 2,5-3,2
III		10 ↕ 3,6
IV		16 ↕ 4,1-4,5
V		25 ↕ >4,5

# Puberty evaluation

- Tanner classification.
- In girls.



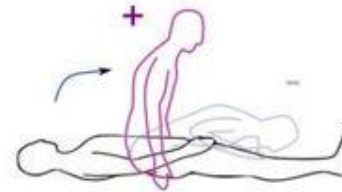
# Meningeal irritation signs

- Pulsing fontanel.
- Neck oposition.
- Brudzinsky's.
- Amos'.
- Spine sign.
- Kernig's.
- Lasegue's.



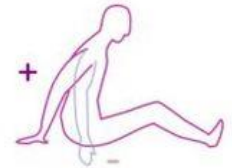Příznak Brudzinského

[https://www.wikiskripta.eu/w/Brudzinsk%C3%A9ho\\_p%C5%99%C3%ADznak](https://www.wikiskripta.eu/w/Brudzinsk%C3%A9ho_p%C5%99%C3%ADznak)



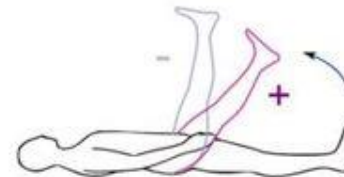Příznak spinální

[https://www.wikiskripta.eu/w/Spine\\_sign](https://www.wikiskripta.eu/w/Spine_sign)



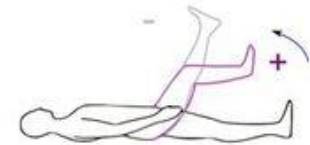
Příznak trojnožky

[https://www.wikiskripta.eu/w/P%C5%99%C3%ADznak\\_trojno%C5%BEky](https://www.wikiskripta.eu/w/P%C5%99%C3%ADznak_trojno%C5%BEky)



Lasegueův příznak

[https://www.wikiskripta.eu/w/Lasegue%C5%AFv\\_p%C5%99%C3%ADznak](https://www.wikiskripta.eu/w/Lasegue%C5%AFv_p%C5%99%C3%ADznak)



Kernigův příznak

[https://www.wikiskripta.eu/w/Kernig%C5%AFv\\_p%C5%99%C3%ADznak](https://www.wikiskripta.eu/w/Kernig%C5%AFv_p%C5%99%C3%ADznak)



Thank you for your attention